

## CASE REPORT

*Abdullah Fatteh,<sup>1</sup> M.D., Ph.D., LL.B.; S. B. Gore,<sup>1</sup> M.D.; G. T. Mann,<sup>1</sup> M.D.; and Keene Garvin,<sup>1</sup> M.D.*

### Suicide with Two Guns: A Unique Case

---

**REFERENCE:** Fatteh, A., Gore, S. B., Mann, G. T., and Garvin, K., "Suicide with Two Guns: A Unique Case," *Journal of Forensic Sciences*, JFSCA, Vol. 25, No. 4, Oct. 1980, pp. 883-885.

**ABSTRACT:** A unique case of suicide using two guns fired at the same time is reported. The victim, a 27-year-old white male with a history of depression, used a pistol to fire a shot in the precordial area and a revolver to fire a shot in the right temporal area. Pertinent autopsy findings are described.

**KEY WORDS:** pathology and biology, suicide, ballistics

In the United States, suicides are committed more often with guns than with any other agent. In most cases, a suicide is accomplished with one shot. Occasionally, the victim fires more than one shot, but this is uncommon. In a series of 844 cases of suicides with guns in North Carolina, 831 cases showed only one gunshot wound each and the remaining 13 cases showed two gunshot wounds each [1]. In eight of these 13 cases each victim fired two shots in the chest, in two victims both gunshot wounds were in the temple area, and three victims had gunshot wounds in the head as well as in chest areas. Only one of the two wounds inflicted was fatal. In all of these cases, each victim had used one gun. In the English literature we are unable to find any record of a case of suicide using two guns. Such a case is described in this paper.

#### Report of a Case

A 27-year-old white male lived alone in one unit of a duplex. At 6:30 p.m., on 26 Nov. 1977, his neighbors in the adjoining unit heard a loud thumping noise. The neighbors, becoming concerned about the noise, knocked on the man's apartment door but got no response. However, through a window they could see the man slumped in a chair. Police were called and when they entered the apartment, through the unlocked front door, they found the man dead.

Received for publication 1 Nov. 1979; revised manuscript received 12 Feb. 1980; accepted for publication 15 Feb. 1980.

<sup>1</sup>Deputy medical examiner, assistant medical examiner, medical examiner, and assistant medical examiner, respectively, Office of the Medical Examiner of Broward County, Fort Lauderdale, Fla.

They observed a gunshot wound in the right temporal area and another in the precordial area. There was a handgun in each of the decedent's hands, which were on his abdomen. The gun in the right hand was a chrome-plated .22-caliber four-shot semi-automatic pistol. The bottom left cartridge had been fired and the other three were unfired. The cartridges were .22-caliber hollow-point type. The index finger of the right hand was in the trigger-pulling position. In the left hand was a .22-caliber H & R model nine-shot revolver. This was also loaded but one shot had been fired. The left thumb was in the trigger area of the revolver. Both guns were firmly gripped by the hands (Figs. 1 and 2). The television set and the stereo in the room were turned on loud. On a table next to the body were two boxes of .22-caliber cartridges, a three-quarters full bottle of tequila, and an almost empty can of beer. The apartment was otherwise neat with no signs of struggle or forced entry. No suicide note was found.

The information from his friends indicated that the victim had been depressed over the fact that he was unable to see his children because of divorce. He was also despondent over an unsuccessful romance with his new girlfriend.

At autopsy, a bullet hole in the white shirt the decedent had been wearing showed considerable amount of gunpowder residue around the margins. The gunshot wound of chest was 38 mm (1 1/2 in.) to the left of midline in the precordial area and measured 4.8 mm (3/16 in.) in diameter. There was a rim of abrasion 4.8 mm wide in its upper margin from the 3 o'clock to 9 o'clock positions. Blackening of skin was obvious around the wound. The bullet traveled backwards, slightly downwards, and to the left, perforating the heart and the left lung. The slightly flattened bullet was found lodged in the tissues of the interspace just below the posterior portion of the left eighth rib 64 mm (2 1/2 in.) from midline.

The gunshot wound in the right temporal area was a contact wound measuring 15.9 by 11.1 mm (5/8 by 7/16 in.). Small lacerations were present in the margins and there was obvious blackening of the skin around the wound. The bullet traveled to the left and slightly backwards. It perforated the cerebral hemispheres, and the slightly deformed bullet was found lodged in the cortex in the left occipitoparietal area.

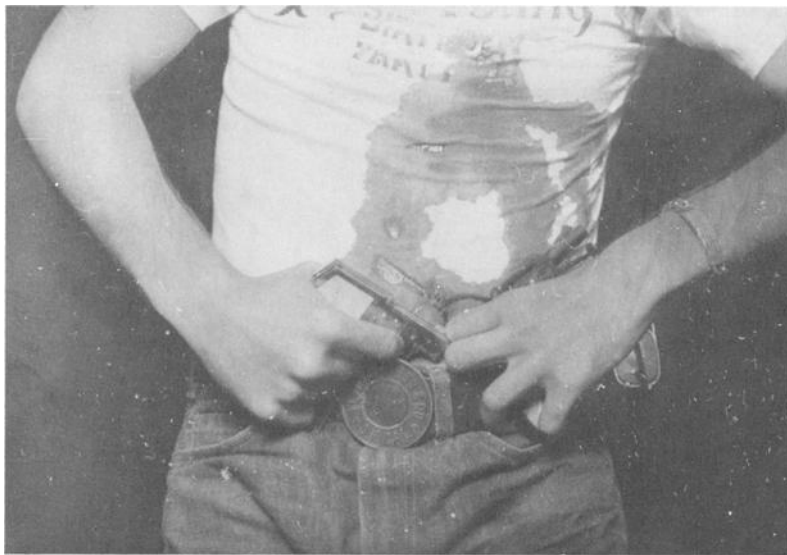

FIG. 1—*Photograph showing a gun gripped by each hand.*

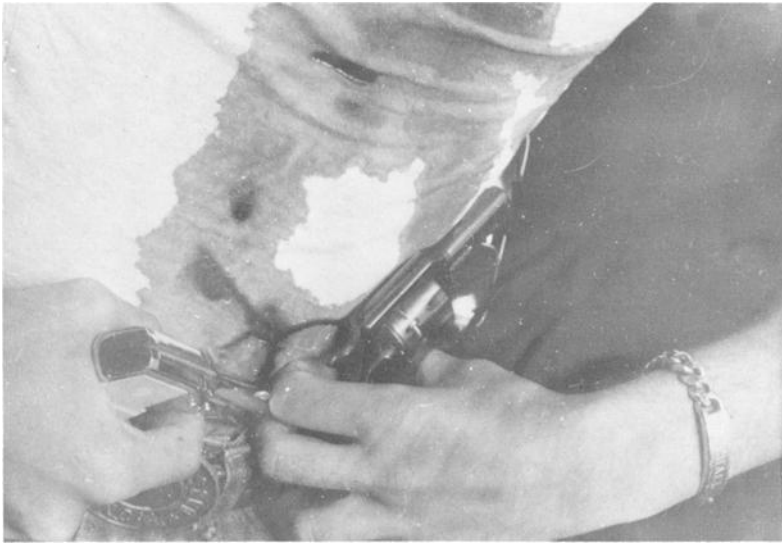


FIG. 2—Photograph showing right index finger in the trigger-pulling position of one gun and left thumb in the trigger area of the other gun.

No obvious gunpowder residue was seen on the hands by naked eye examination. There were no other pertinent findings at autopsy. The analysis of blood revealed an alcohol concentration of 0.15%.

On the basis of the circumstances and autopsy findings this case was ruled a suicide.

### Summary

A unique case of suicide using two guns is described. One hand was used to fire each gun. Both guns were fully loaded and one shot was fired from each gun. Both shots inflicted fatal injuries. In view of this and in view of a single loud thumping sound heard by the neighbors, it appears most likely that both shots were fired simultaneously.

### Reference

[1] Fatteh, A., *Medicolegal Investigation of Gunshot Wounds*, Lippincott, Philadelphia, 1976.

Address requests for reprints or additional information to  
 Abdullah Fatteh, M.D., Ph.D., LL.B.  
 Office of the Medical Examiner, Broward County  
 5301 S.W. 31st Ave.  
 Fort Lauderdale, Fla. 33312